



Intratendinous ganglion cyst of peroneus brevis tendon and its reconstruction with semitendinosus graft

Intratendinozna ganglijska cista tetive kratkog peronealnog mišića i njena rekonstrukcija sa semitendinoznim graftom

Igor Frangež, Tea Nizič Kos, Matej Cimerman

University Clinical Center Ljubljana, Department of Traumatology, Ljubljana, Slovenia

Abstract

Introduction. A ganglion cyst is a common benign tumor, mainly found in the wrist and ankle. The ones originating from a tendon, such as in our case, are the most rare. The ganglion cyst presents with a variety of symptoms, offering a wide range of possible differential diagnoses. Physical examination is crucial to make an accurate diagnosis, but magnetic resonance imaging (MRI) can help in identifying the ganglion cyst. The treatment is mostly conservative, but in cases when the ganglion cyst disables the patient's ability for normal life functioning, due to pain and decreased mobility, surgery is necessary. **Case report.** A 38-year-old female with persistent ankle pain and edema was clinically diagnosed with luxation of peroneal tendons. Further investigation with MRI showed tenosynovitis of peroneal tendons and rupture of the superior peroneal *retinaculum* with an intratendinous ganglion cyst of *peroneus brevis* tendon. Surgical treatment with the reconstruction of *peroneus brevis* and peroneal *retinaculum* was performed with semitendinosus graft and anchor sutures. Histology confirmed the diagnosis of the intratendinous ganglion. After four months of rehabilitation, the patient returned to normal daily and sports activities and was pain-free on the follow-up. No recurrence of the ganglion cyst was acknowledged. **Conclusion.** Surgery is crucial for patients with intratendinous ganglion cyst and symptomatic instability of the peroneal tendons with chronic subluxation.

Key words:

leg injuries; ganglion cysts; tendons; orthopedic procedures; transplants; treatment outcome.

Apstrakt

Uvod. Ganglijska cista je čest benigni tumor, uglavnom pronađen u zglobovima, nasuprot našem primeru, gde ganglijska cista poreklom iz tetive, po svim klasifikacijama predstavlja najređi izvor. Ganglijska cista se ispoljava različitim simptomima i nudi širok raspon mogućih diferencijalnih dijagnoza. Fizikalni pregled je od ključne važnosti za stvaranje tačne dijagnoze, ali magnetna rezonanca (MR) može pomoći u identifikaciji ganglijskih cisti. Lečenje je uglavnom konzervativno, ali u slučajevima kada ganglijska cista uzrokuje bolove i smanjuje funkciju i onemogućuje sposobnost pacijenta za normalan život, potrebna je operacija. **Prikaz bolesnika.** Žena stara 38 godina sa upornim bolovima u skočnom zglobu, sa edemom u obrnutoj everziji stopala, obavila je pregled kod specijaliste traumatologa, koji je indikovao dalju dijagnostiku. Snimak magnetne rezonance (MR) pokazao je da se radilo o tendosinovitisu peronealne tetive i rupturi gornjeg peronealnog *retinaculum* sa intratendinoznom ganglijskom cistom u tetivi *musculus peroneus brevis-a*. Pacijentkinja je hirurški lečena, napravljena je adhezioziza, resekcija tetive *musculus peroneus brevis-a* u kojoj je bila ganglijska cista. Posle toga, rekonstruisana je resecirana tetiva sa semitendinoznim graftom i sidro šavovima. Histološki je potvrđena dijagnoza intratendinozne ganglijske ciste. Postoperativno, noga je bila imobilizirana u gipsu, sa 5 stadijuma everzije i neutralnim položajem, a posle toga bila je podvrgnuta krioterapiji i kasnije fizioterapiji. **Zaključak.** Hirurški zahvat je odlučujući za simptomatske pacijente sa intratendinoznom ganglijskom cistom, sa znakovima nestabilnosti peronealne tetive i hroničnom luksacijom.

Ključne reči:

noga, povrede; ciste, ganglijske; tetive; ortopedske procedure; graftovi; lečenje, ishod.

Introduction

Ganglion cysts are most commonly found benign masses in the area of hand, wrist, shoulder, knee or ankle¹. They vary in size, are mainly solitary and occur in younger people, aged from 15 to 40, more frequently in women^{1,2}. Their classifica-

tion is based not only on the location of the ganglion cyst but also on its origin. They can arise from bones, joints, soft tissues and tendon sheaths. Although they are common, those originating from a tendon, the so-called intratendinous ganglion cysts, are the rarest, especially in the area of the ankle, or more precisely in the area of peroneal tendon^{1,3}.

The etiology of the formation of the ganglion cyst is not well understood, but many agree with the hernial hypothesis, which correlates its formation with the distention of a weakened area of the tendon, where consequently ganglion forms¹. In one-third of the cases conditions as local trauma or increased burden and stress to the part where the ganglion forms are associated with its development. Researchers associate the ganglion cyst formation with degenerative and inflammatory conditions of soft tissue or bone^{1,3}.

When identifying the mass of an unknown origin, many differential diagnoses are considered. Patient's history and status should be taken thoroughly, focusing on the accompanying trauma of the area, onset of symptoms and possible relation to increased activity¹⁻³. Physical examination is crucial in making the accurate diagnosis by palpation of the mass. To exclude possible bone lesions X-ray should be performed. Ultrasound of soft tissue can be beneficial. The most reliable method to determine the accurate location, the involvement of adjacent structures and the size of the ganglion cyst is magnetic resonance imaging (MRI)¹⁻⁴.

Treatment decision depends on the presence of pain and impaired ankle eversion. In most cases, conservative measures are taken, such as immobilization of the involved joint. Semi-invasive treatment includes aspiration of the cyst or injection of anti-inflammatory agents (for example corticosteroids) into the cyst. This method has a high recurrence rate.

The third option is surgery, which is the method of choice in case of severe, chronic and symptomatic ganglion cyst¹⁻³.

Case report

A 38-year-old female was examined at the emergency department where she reported a crack and later pain in the lateral side of the ankle during walking. Ankle sprain was diagnosed and functional treatment was advised. After one month she complained of increasing pain and edema on the lateral side of the ankle. Clinical examination revealed edema at the lateral side, inversion position of the foot with painful palpation, especially on the anterior talofibular ligament and fibular malleolus from the lateral and posterior side with palpable formation retromalleolarly, in the course of *peroneus brevis* tendon (Figure 1). X and ultrasound revealed no pathology. Clinical diagnosis of luxative peroneal tendons with superior peroneal retinaculum rupture was established. MRI was performed to confirm the clinical diagnosis and showed tendinosis of peroneal tendons with severe synovitis, intratendinous ganglion cyst of the peroneus brevis tendon and rupture of the superior peroneal *retinaculum*. Due to clinical findings and MRI results, the surgical treatment decision was made. Adhesiolysis was performed followed by reconstruction of peroneus brevis tendon defect and superior peroneal *retinaculum* with semitendinosus graft (Figures 2 and 3) that was proximally fixated by anchor suturing the

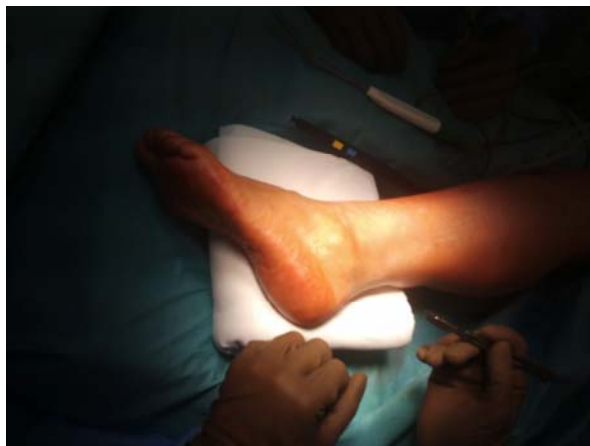

Fig. 1 – Left ankle with lateral edema.

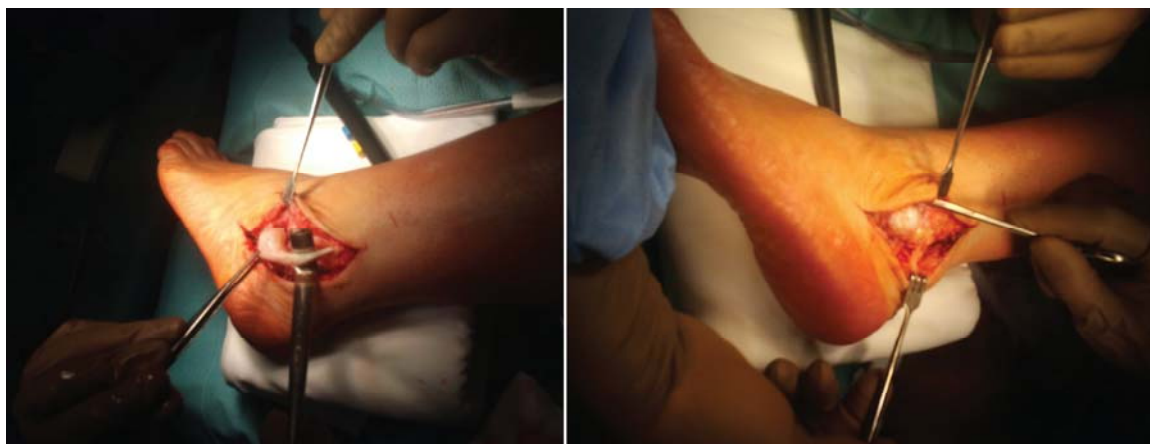

Fig. 2 – *Peroneus brevis* ganglion in surgery.

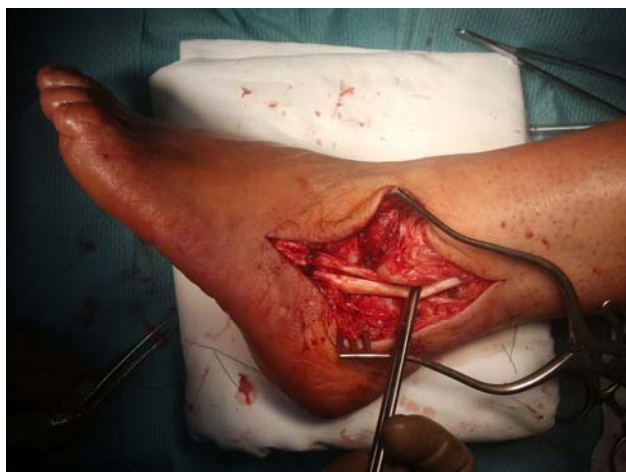

Fig. 3 – Reconstruction of *peroneus brevis* tendon defect and superior peroneal retinaculum with semitendinosus graft.

graft to the remainder of retinaculum (Figure 4). At operation, peroneal sulcus appeared too shallow and it was deepened to avoid reoccurrence of the peroneal tendon luxation. Histology confirmed the intratendinous ganglion cyst.

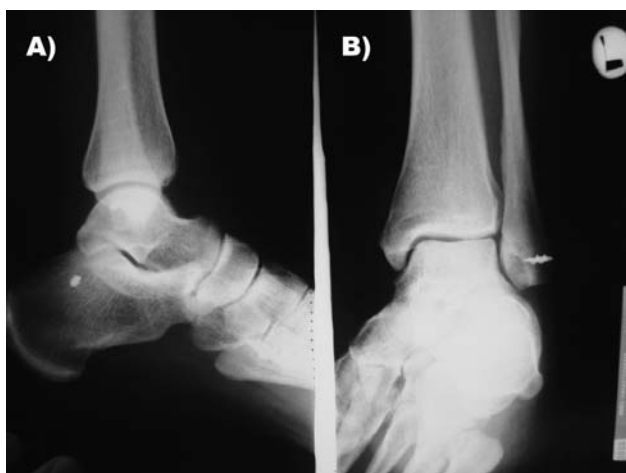


Fig. 4 – A) Fixation of semitendinosus graft with anchor sutures, where anchor is seen on the X-ray, and B) distally suturing the graft to the remainder of retinaculum.

Postoperatively she received a below-knee non-weight-bearing cast in 5 degrees eversion and neutral position for six weeks (Figure 5). After one year follow-up, there was no recurrence of symptoms. Cryotherapy with immediate verticalisation was indicated after the operation. Control X-ray showed the stable position of the operated foot. Afterwards, the cast was replaced by a weight-bearing one for another 2 weeks. When the cast was removed, she was referred to physiotherapy. After four months she was able to go back to work and her after daily activities.

Discussion

Although ganglion cysts are the most common soft tissue pathology, they are quite rare in the peroneal tendons¹. Peroneal tendon tears are a common cause of chronic lateral ankle pain, but in many cases remain untreated due to mis- or undiagnosis⁵⁻⁷.

Peroneal tendon pathology is common but rarely mentioned in the literature. Reports found in the literature are all from a distant history, no new cases have been described¹⁻¹². Therefore we presented a case where we reconstructed a retinaculum as well as the defect of *peroneus brevis* tendon after excision of the ganglion cyst with semitendinosus graft.

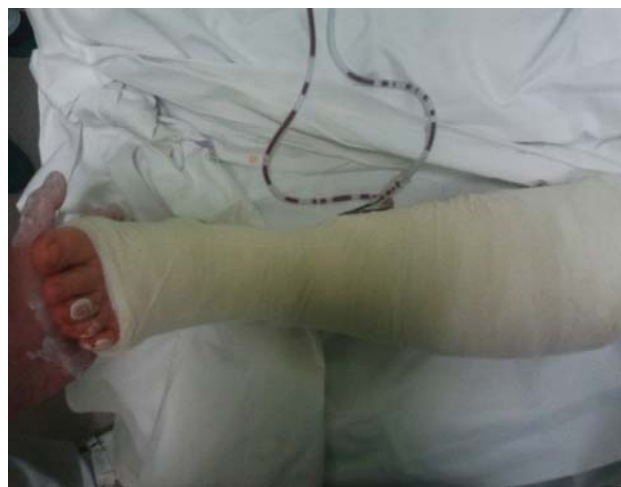

Fig. 5 – Below-knee non weight bearing cast in 5 degree eversion and neutral position.

Since symptoms of the ganglion cyst are unspecific, palpable and/or visible swelling and pain, and because the differential diagnosis is wide, the ganglion cyst of the peroneal tendon is commonly overlooked or wrongly diagnosed¹.

In making the diagnosis we can perform an X-ray, which mainly helps in narrowing the possible differential diagnoses^{1,3}. As in our case, X-ray of such patients is usually normal. It is not uncommon that osteophyte formations are present in the adjacent surfaces of the bone or joint¹. The best technique to confirm the diagnosis is MRI, which in our case showed severe tenosynovitis, formed intratendinous cyst and undefined upper retinaculum of the peroneus^{1,4}. Tenosynovitis and tendon tears are commonly present to a tendinous ganglion cyst and therefore represent a major differential diagnosis based on MRI⁴. Excluding differentials it is very important to first exclude those that are endangering the patient, such as synovial sarcoma, myxoid chondrosarcoma or liposarcoma and distant metastasis to a primary tumor, if such is known^{1,4}.

However, Costa et al.⁴ suggest that MRI findings of a lobulated mass within the tendon with rich enhancement suggest the diagnosis of an intratendinous ganglion cyst. To absolutely confirm the diagnosis, histology is crucial.

Once the diagnosis is confirmed, treatment can be performed by aspiration and injection with cortisone, operation by removal of the ganglion cyst or conservatively with or without a cast^{1,3}. Every method has its side effects and success rate is variable, but common to all is the recurrence of the ganglion cyst with varying probability, the highest being in semi-invasive method¹.

The main criterion by which we decided what treatment method will be used is the duration of symptoms, whether it is the acute or chronic course of signs and symptoms such as swelling, pain.

In case of chronic ganglion cyst with symptomatic instability of the peroneal tendons, surgery is preferred. There are many different surgical techniques described in the literature⁸. In our case we performed adhesiolysis, that suggested on the ganglion formation after trauma, infection or inflammation, we already discussed as a cause for the formation of ganglion cyst and was noted in the MRI report. Afterwards, revision of peroneal tendon and removal of the ganglion cyst took place. We needed to reconstruct the ruptured the peroneus brevis tendon and peroneal *retinaculum*, by using semi-tendinosus graft. Such procedure was described by Paterson et al.⁹ who reported that by performing semi-tendinosus graft reconstruction of the peroneal tendons, its function was obtained.

Additionally, we performed deepening of peroneal sulcus due to the shallowness of the sulcus, in order to prevent peroneal tendon further luxation and to increase its long-term stability. Peroneal sulcus is important since it allows peroneal tendons to move along it⁸.

Possibilities for surgical repair and reconstruction of peroneal tendon tears are with or without the fibular osteotomy, by transposition of the tendon, by anchor sutures of the tendon or with the use of a graft, as used in our case^{7, 9-11}. The method of fibular osteotomy is the application of the *retinaculum* and augmentation with the calcaneofibular ligament, deepening on the depth of peroneal sulcus, which is shallow in most of the reported cases⁹⁻¹¹. The shallow peroneal sulcus is the second most common cause of peroneal subluxation, right after the ankle sprain^{8, 9}.

Our patient was postoperatively immobilized and later reported being satisfied by the outcome. We can not correlate the success rate with the immobilization since there are studies reporting that time of immobilization does not affect the outcome^{10, 12}.

At the emergency department, where such patients mostly receive the first check-up, such conditions should be somewhere in the subconsciousness of the doctor, especially in patients, that report prolonged ankle pain, lateral swelling, ankle instability and chronic ankle sprains^{2, 3, 6, 12}. Since imaging available at the emergency department is not suitable for making a diagnosis of peroneal tendon subluxation or dislocation due to the ganglion cyst, when suspecting such pathology, these patients should be referred to a foot and ankle specialist, for further investigations and management. This painful condition requires surgery⁸.

Conclusion

This case report presents a rare chronic intratendinous ganglion cyst arising from *peroneus brevis* tendon that was surgically treated by its excision and by reconstruction of tendon brevis and superior peroneal *retinaculum*, using the semitendinosus graft.

It is important to diagnose these conditions that are causing chronic pain to the patient and to allow the patient to have a normal quality of life. Four months post surgery our patient returned to normal daily and sports activities and reported having no problems. No recurrence of the ganglion cyst was acknowledged.

R E F E R E N C E S

1. *Camasta CA*. Excision of the ganglion cyst. 1993. p. 181–5.
2. *Rozbruch SR, Chang V, Bohne WH, Deland JT*. Ganglion cysts of the lower extremity: an analysis of 54 cases and review of the literature. *Orthopedics* 1998; 21(2): 141–8.
3. *Zgonis T, Jolly GP, Polyzois V, Stamatis ED*. Peroneal tendon pathology. *Clin Podiatr Med Surg* 2005; 22(1): 79–85.
4. *Costa C, Morrison WB, Carrino JA, Raiken SM*. MRI of an intratendinous ganglion cyst of the peroneus brevis tendon. *AJR Am J Roentgenol* 2003; 181(3): 890–1.
5. *Dombek MF, Lamm BM, Saltrick K, Mendicino RW, Catanzariti AR*. Peroneal tendon tears: a retrospective review. *J Foot Ankle Surg* 2003; 42(5): 250–8.
6. *Krause JO, Brodsky JW*. Peroneus brevis tendon tears: pathophysiology, surgical reconstruction, and clinical results. *Foot Ankle Int* 1998; 19(5): 271–9.
7. *Oliva F, Ferran N, Maffulli N*. Peroneal retinaculoplasty with anchors for peroneal tendon subluxation. *Bull Hosp Jt Dis* 2006; 63(3–4): 113–6.
8. *Mendesoon M, McVey JT, MacEvoy A*. Surgical Correction of Subluxing Peroneal Tendons Utilizing a Lateral Slip of the Achilles Tendon: A case report. *Foot Ankle Online J* 2009; 2(8): 3.
9. *Paterson R, Cohen B, Taylor D, Bourne A, Black J*. Reconstruction of the lateral ligaments of the ankle using semi-tendinosis graft. *Foot Ankle Int* 2000; 21(5): 413–9.
10. *Porter D, McCarroll J, Knapp E, Torma J*. Peroneal tendon subluxation in athletes: fibular groove deepening and retinacular reconstruction. *Foot Ankle Int* 2005; 26(6): 436–41.
11. *Kaz AJ, Coughlin MJ*. Technique tip: Distal fibula rotational osteotomy for subluxating peroneal tendons. *Med Chir Pied* 2007; 23: 68–71.
12. *Ogawa BK, Thordarson DB*. Current concepts review: peroneal tendon subluxation and dislocation. *Foot Ankle Int* 2007; 28(9): 1034–40.

Received on May 21, 2015.
Revised on May 11, 2016.
Accepted on May 12, 2016.
Online First October, 2016.